



Screening the athlete's shoulder for impingement symptoms: a clinical reasoning algorithm for early detection of shoulder pathology

A M Cools, D Cambier and E E Witvrouw

Br. J. Sports Med. 2008;42:628-635; originally published online 3 Jun 2008;
doi:10.1136/bjsem.2008.048074

Updated information and services can be found at:

<http://bjsm.bmj.com/cgi/content/full/42/8/628>

These include:

References

This article cites 64 articles, 30 of which can be accessed free at:

<http://bjsm.bmj.com/cgi/content/full/42/8/628#BIBL>

Rapid responses

One rapid response has been posted to this article, which you can access for free at:

<http://bjsm.bmj.com/cgi/content/full/42/8/628#responses>

You can respond to this article at:

<http://bjsm.bmj.com/cgi/eletter-submit/42/8/628>

Email alerting service

Receive free email alerts when new articles cite this article - sign up in the box at the top right corner of the article

Notes

To order reprints of this article go to:

<http://journals.bmj.com/cgi/reprintform>

To subscribe to *British Journal of Sports Medicine* go to:

<http://journals.bmj.com/subscriptions/>

Screening the athlete's shoulder for impingement symptoms: a clinical reasoning algorithm for early detection of shoulder pathology

A M Cools, D Cambier, E E Witvrouw

Department of Rehabilitation Sciences and Physiotherapy, Faculty of Medicine and Health Sciences, University Hospital, Ghent, Belgium

Correspondence to: Ann Cools, University Hospital Ghent, Department of Rehabilitation Sciences and Physiotherapy, De Pintelaan 185, 383, B9000 Gent, Belgium; ann.cools@ugent.be

Accepted 14 April 2008
Published Online First
3 June 2008

ABSTRACT

Chronic shoulder pain and dysfunction are common complaints among overhead athletes seeking care from physical medicine and rehabilitation. Impingement is a frequently described pathological condition in the overhead athlete. Impingement symptoms may be the result of rotator cuff pathology, shoulder instability, scapular dyskinesis or muscle dysfunction, biceps pathology, SLAP lesions and chronic stiffness of the posterior capsule. At present, numerous different shoulder tests have been described in literature and discussed with respect to their individual diagnostic accuracy. However, in view of the number of shoulder tests, it is often a challenge for the clinician to select the appropriate tests for diagnosing the underlying pathology. The purpose of this paper is to present and discuss a clinical algorithm which may be used in the early detection of the underlying causes of impingement symptoms. In this algorithm, a specific chronology and selection of diagnostic tests may offer the clinician a guideline in his physical examination of the athlete with shoulder pain.

Impingement is one of the most frequently described pathological shoulder conditions in general practice and in sports medicine.^{1–3} Early literature described impingement as a pathology or a diagnosis⁴ but today impingement is considered to be a cluster of symptoms, rather than a pathology itself. Various investigations have confirmed the association between impingement symptoms and a variety of underlying pathological mechanisms. Rotator cuff pathology,^{1 5 6} scapular dyskinesis,^{7–9} shoulder instability,^{10–12} biceps pathology and SLAP lesions,^{13 14} and glenohumeral internal rotation deficit^{13 15} have been suggested to cause shoulder impingement symptoms. The purpose of this paper is to help the clinician define the specific kind of impingement, and to deduce the possible underlying pathological mechanism in the office setting.

This may be of particular relevance in the early screening and prevention of chronic shoulder pain. Athletes involved in overhead sports often exhibit a vague discomfort in their shoulder. Early detection of these symptoms, with appropriate management, likely improves clinical outcome. However, a confusing array of clinical tests have been described for a large variety of shoulder pathologies,^{16–18} and the clinician has to select among these tests to examine the patient in an office consultation. In this paper we (i) describe and define impingement, (ii) present an algorithm for clinical reasoning, and (iii) discuss the clinical and diagnostic value of these tests.

DEFINITION OF IMPINGEMENT

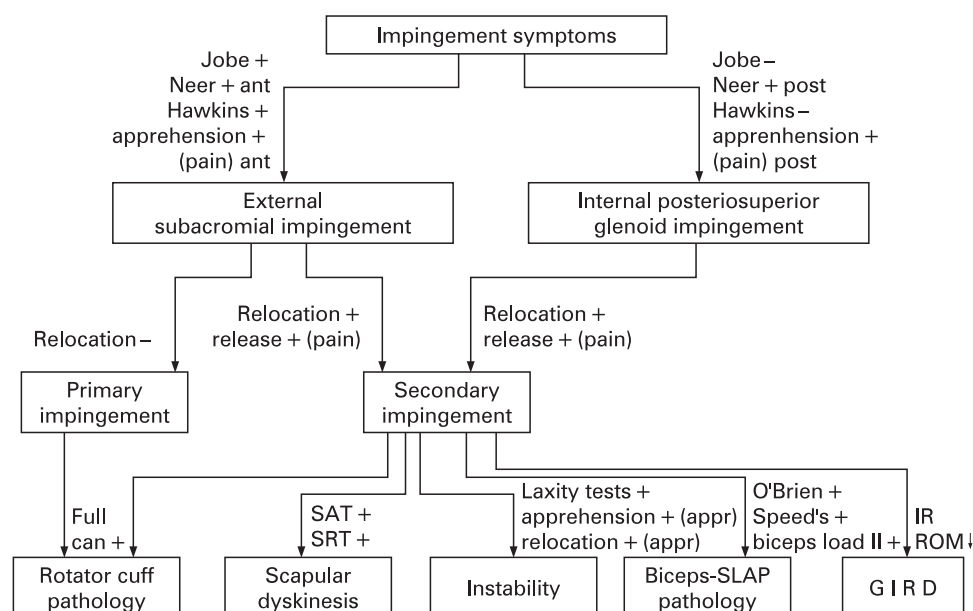
The literature describes two types of impingement: subacromial⁴ and internal.¹⁹ Subacromial or external impingement is the mechanical encroachment of the soft tissue (bursa, rotator cuff tendons) in the subacromial space between the humeral head and the acromial arch.⁴ This encroachment particularly takes place in the midrange of motion, often causing a “painful arc” during active abduction.

Internal impingement comprises encroachment of the rotator cuff tendons between the humeral head and the glenoid rim.¹⁹ Based on the location of the impingement, anterosuperior^{20 21} and posterosuperior^{19 22 23} glenoid impingement have been described. Since anterosuperior glenoid impingement is less common, and literature is scarce,²¹ it is not discussed further in this paper. Posterosuperior glenoid impingement has been well-described in literature since the first paper of Walch *et al.*¹⁹ It consists of the mechanical encroachment of the rotator cuff tendons, particularly the tendon of the m. supraspinatus and infraspinatus, between the greater tubercle of the humerus and the posterosuperior rim of the glenoid. This friction occurs specifically during the late cocking position of throwing, which is maximal external rotation, horizontal abduction, and, depending on the specific sport discipline, a certain amount of abduction. Because of the specific position of this internal impingement, it is considered to be the primary cause of chronic shoulder pain in the overhead athlete.⁵

Besides the classification of impingement based on the site of encroachment, very often impingement is classified based on the cause of the problem, dividing it into primary versus secondary impingement.^{14 23 24} In primary impingement, a structural narrowing of the subacromial space causes pain and dysfunction, such as acromioclavicular arthropathy, type I acromion, or swelling of the soft tissue in the subacromial space.^{25 26} In secondary impingement, there are no structural obstructions causing the encroachment, but rather functional problems, occurring only in specific positions.^{1 8} Secondary impingement may occur in the subacromial space as well as internally in the glenohumeral joint.

In view of the assumption that impingement symptoms may be the result of various underlying pathologies, it is important to describe the biomechanical relationship between these symptoms and shoulder diagnoses. Rotator cuff pathology may be associated with impingement symptoms in primary as well as secondary impingement. In primary impingement, swelling of the injured rotator cuff

Figure 1 Algorithm for clinical reasoning in the examination of impingement-related shoulder pain.



tendons causes the narrowing of the subacromial space;²⁷ in secondary impingement, dysfunction of the rotator cuff (whose function is, amongst others, to perform a caudal glide of the humeral head during elevation in order to avoid impingement) results in more cranial migration of the humeral head, thus causing secondary impingement.¹

Scapular dyskinesis also has been described in relation to impingement symptoms.⁷⁻⁹ The rationale behind this association is that, during arm elevation, impingement may occur if the scapula insufficiently follows the humeral head movements because of a lack of upward rotation, posterior tilting, and external rotation.⁷⁻²⁸

The association between impingement symptoms and shoulder instability is well established. Excessive humeral head translations, based on capsular laxity and instability,¹⁰⁻¹⁵ cause temporal narrowing of the subacromial space or the glenohumeral joint relation, thus leading to impingement symptoms and pain.

Since the biceps plays an important role in shoulder stability and function,²⁹⁻³¹ biceps pathology may cause secondary impingement symptoms. Indeed, biceps tendon problems (tendinopathy or tenosynovitis) as well as SLAP lesions (labral lesions at the site of origin of the long head of the biceps) compromise optimal shoulder function, and may result in impingement.¹⁴

Glenohumeral Internal Rotation Deficit, often referred to as GIRD, is a sport-specific adaptation of posterior shoulder structures to chronic excessive overload of these structures during frequent throwing.^{12-27, 32-33} There are several theories concerning the occurrence and development of GIRD. Burkhart *et al*¹³ report that GIRD occurs before any other motion adaptation, suggesting that contracture of the posterior capsule is to blame for this change in range of motion, and is sometimes followed by associated gains in ER. Other researchers believe that GIRD begins in the early years of overhead throwing with a bony adaptation of the humerus.³⁴ A third hypothesis regarding the cause of GIRD is muscle hypertony in the external rotators due to frequent eccentric loading.¹⁰

CLINICAL REASONING IN PATIENT INVESTIGATION

The physical examination of the overhead athlete consists initially of a thorough history (or subjective assessment),

inspection, active, passive and resistance tests, and pre-examination and postexamination palpation. This paper focuses on physical examination after the clinician suspects sports-related impingement pain. During the physical examination of the athlete with shoulder pain, it is imperative that the investigator examines what kind of impingement the patient suffers from, and what the underlying pathology might be. The algorithm shown (fig 1) offers the clinician an approach to specific tests that can be used when screening the athlete's shoulder for impingement-related shoulder problems, and proposes a particular chronology in the performance of the individual tests.

Impingement tests

Of the various provocative impingement tests, the most popular are the Jobe, Hawkins and Neer tests.¹⁶ The Jobe test (fig 2) is positive for subacromial impingement if the patient reports pain at the injured side. The test will be negative if the patient has posteriosuperior glenoid impingement. A painful Hawkins test (fig 3) is an indication for subacromial impingement; the test



Figure 2 Impingement test: Jobe (empty can): both shoulders are put in 90° elevation in the scapular plane in maximal internal rotation (empty-can position) and manual resistance is given against further elevation.

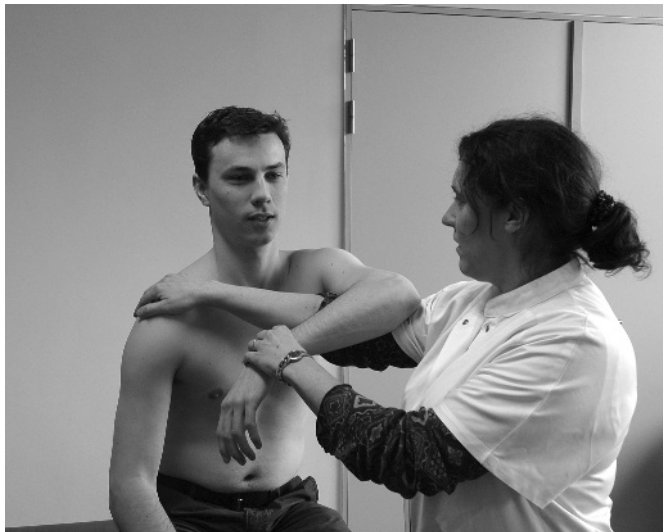

Figure 3 Impingement test: Hawkins: passive internal rotation is performed with the shoulder in 90° of forward flexion.

will be negative in case of internal impingement. Interpretation of the Neer test (fig 4) depends upon the location of the pain. Pain at the front of the shoulder is an indication for subacromial impingement, whereas patients with internal impingement will exhibit pain at the posterior aspect of the shoulder.

Besides these impingement tests instability tests are very often used as provocation tests for impingement.³⁵ Researchers use the Apprehension Test and the Relocation Test, interpreting them with respect to pain rather than instability symptoms, to further define the cause of impingement.^{17 36-40} Pain during the

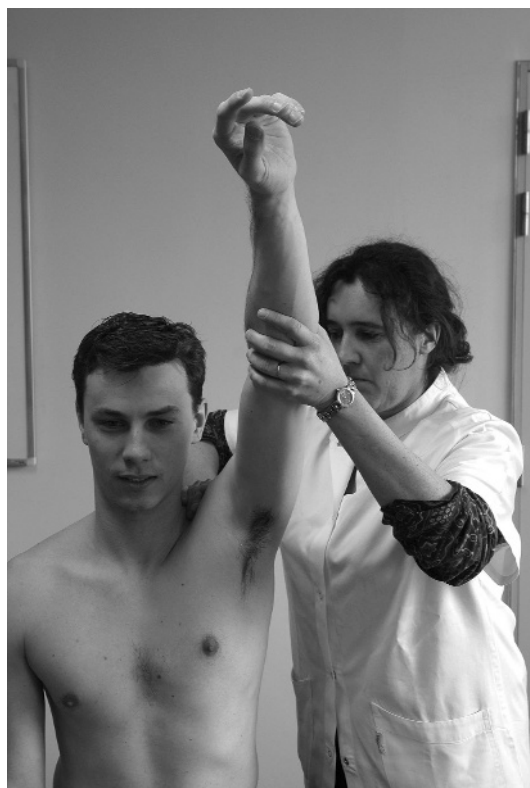

Figure 4 Impingement test: Neer: the examiner performs forced maximal forward flexion with the scapula fixed into depression.

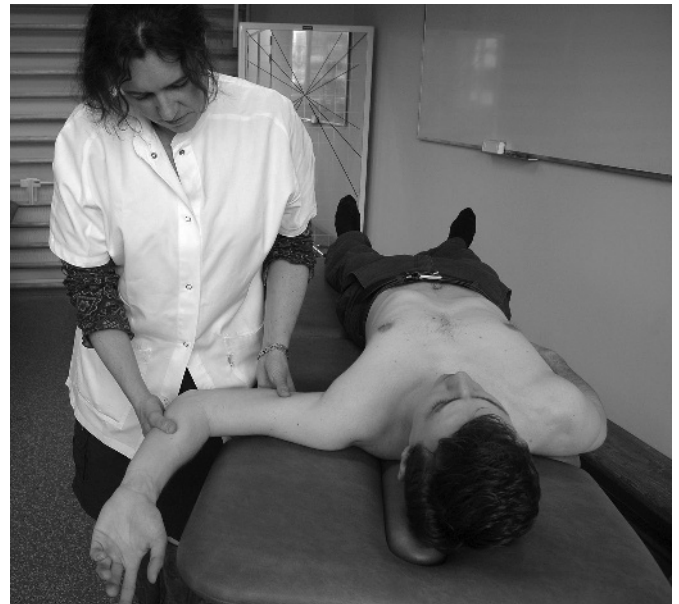

Figure 5 The apprehension test: the shoulder is placed passively in maximal external rotation, and horizontal abduction.

apprehension test (fig 5) at the anterior aspect of the shoulder suggests subacromial impingement; pain at the posterior aspect implies posterosuperior glenoid impingement.⁴⁰ The relocation test (fig 6) is performed subsequent to the apprehension test. The test is positive if the pain, exhibited during apprehension, disappears.^{17 41} The relocation test allows us to identify primary versus secondary impingement. If the test is positive, this means that the impingement pain is secondary, based on excessive anterior translation of the humeral head. A negative test suggests primary impingement, not dependent on the arthrokinematic position of the humeral head.¹

Rotator cuff tests

To define the involvement of rotator cuff pathology in the impingement symptoms, a modified version of the Jobe test is a valuable tool. Indeed, Jobe *et al* described the test to investigate

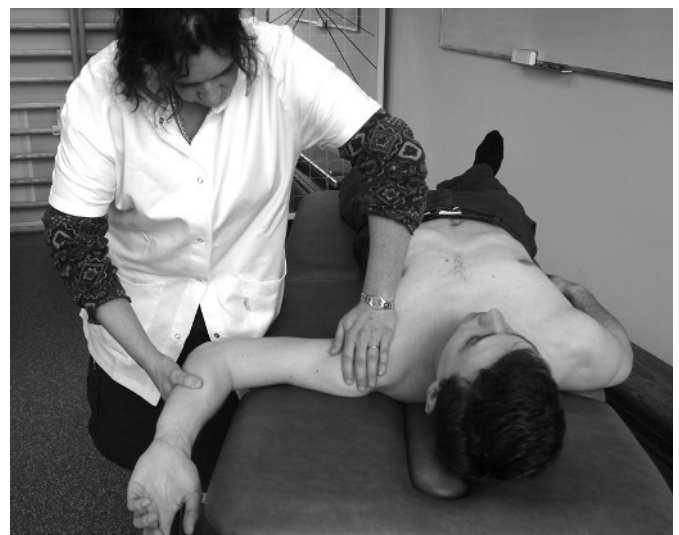

Figure 6 The relocation test: the investigator manually performs a dorsal glide on the humeral head in the apprehension position.

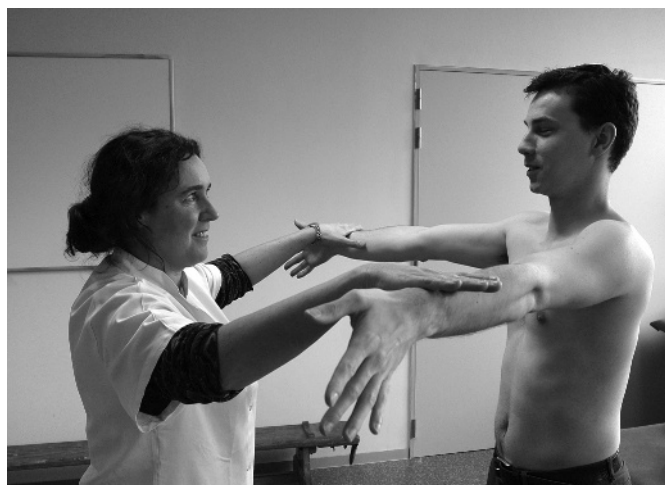

Figure 7 Full-can test: both shoulders are put in 90° elevation in the scapular plane in maximal external rotation (full-can position) and manual resistance is given against further elevation.

the integrity of the rotator cuff muscles, particularly the supraspinatus.⁴² However, based on this test, one cannot define whether a painful test is the result of functional impingement rather than rotator cuff muscle dysfunction. Therefore, the examiner can perform the full-can test (fig 7). Research has indicated that rotator cuff muscles are also highly active in this position.^{43 44} If both tests are painful, rotator cuff pathology is present. If only the empty-can test is painful, and the full-can is negative, the patient probably suffers from impingement symptoms, but not primarily related to rotator cuff pathology. In the presence of rotator cuff pathology, the examiner can perform a number of specific tests for the supraspinatus, subscapularis and infraspinatus in order to find out whether one or more tendons are ruptured.¹⁶ However, rotator cuff tears are outside the scope of this paper.

Scapular involvement tests

Scapular involvement in impingement-related shoulder pain may be examined by the Scapular Assistance Test (SAT)^{8 45} and the Scapular Retraction Test (SRT).^{8 46} In the SAT, scapular movement quality is examined (fig 8). Reduction of pain during this movement compared with non-assistance confirms

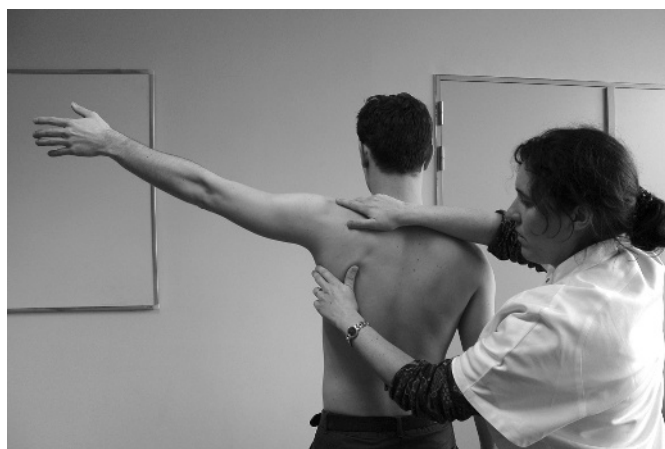


Figure 8 The scapular assistance test: the examiner manually assists correct scapular movement during active elevation of the arm.

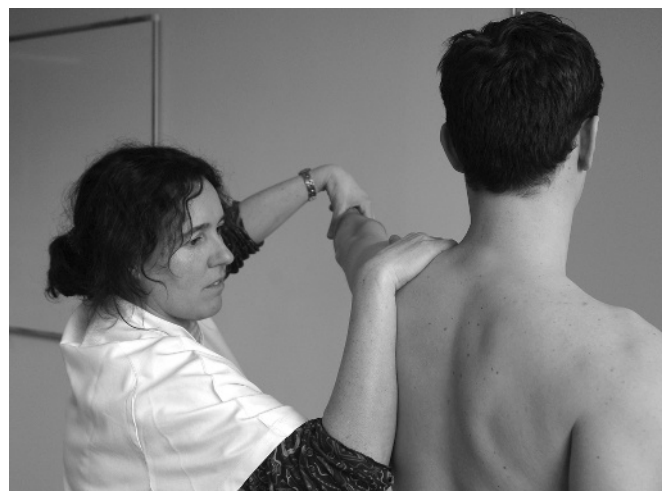

Figure 9 The scapular retraction test: the empty-can test is performed while the examiner stabilises the patient's scapula and shoulder in a position of retraction by placing the forearm along the medial border of the scapula.

scapular involvement in the shoulder complaints. The SRT investigates scapular stability (fig 9). The test is positive for scapular involvement when the initial pain, present in the empty-can position, disappears during the SRT.

Instability tests

The clinical tests to examine shoulder instability can be divided into provocative tests and laxity tests. Commonly used provocative tests for instability are the Apprehension and Relocation tests, described earlier in this paper.^{17 41} In case of instability, patients will exhibit instability symptoms, such as apprehensive muscle tension, and subluxation, rather than pain. Distinct from the provocative tests, the laxity tests assess humeral translation with respect to the glenoid fossa. For anterior laxity, the Load and Shift test may be used^{17 18} (fig 10). The amount of laxity is graded from 1 (translation up to, but not beyond, the glenoid rim) to 3 (subluxation without spontaneous reduction). The sulcus sign allows examination of inferior laxity (fig 11). For posterior laxity, the posterior

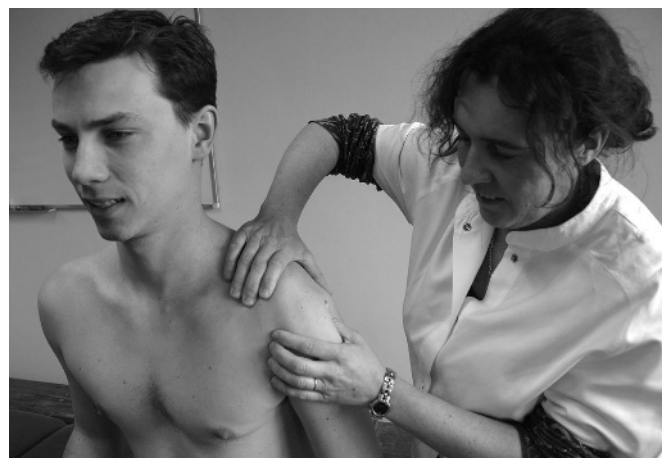

Figure 10 The load and shift test: the humeral head is loaded in such a way as to centre it congruently within the glenoid fossa. Subsequently, the humeral head is manually shifted anteriorly, relative to the glenoid fossa.

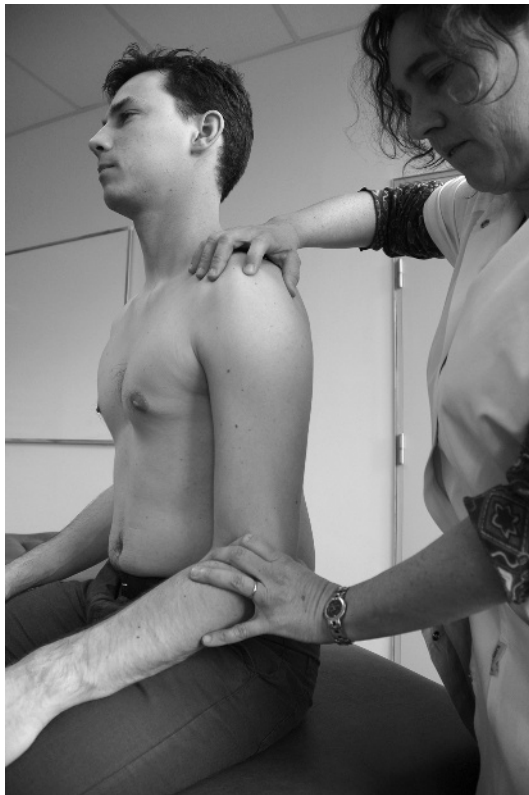

Figure 11 The sulcus-sign: the examiner performs a downward traction on the arm.

subluxation test is described (fig 12). The test is considered to be positive if a clunk is felt during the latter movement, indicating the humeral head is relocated in the glenoid after being subluxated posteriorly.¹⁷

Biceps pathology and SLAP lesion tests

Based on recent literature,^{17 18 47} we recommend the following tests for biceps pathology and SLAP lesions: the Speed's Test (fig 13), the O'Brien Test (fig 14A, B), and the biceps load II test (fig 15). A positive Speeds test produces pain into the biceps region.⁴⁸ The O'Brien test is considered to be positive for SLAP lesions if pain, provoked in the first testing position, is lessened or disappears in the second testing position.⁴⁹ The test result of the Biceps Load II test⁵⁰ is considered positive if the patient complains of pain during the resisted elbow flexion.

Clinical evaluation of GIRD

The assessment of GIRD is performed by measuring glenohumeral internal rotation range of motion⁵¹ (fig 16). Goniometric assessment as well as interpretation of the "end-feel" are described as criteria for GIRD evaluation.⁵² A side difference of 20° is considered to be positive for GIRD.¹³

PUTTING IT ALL INTO PERSPECTIVE – WHAT IS THE CLINICAL UTILITY OF THESE TESTS?

Although a large number of special tests are described for examination of the shoulder,^{16–18 47 53} it is not feasible to undertake all of them in every examination. Here we present and discuss an algorithm for clinical reasoning and physical examination testing to assist the clinician in the assessment of impingement-related shoulder pain. We take into account the accuracy and the diagnostic value of each of these tests.

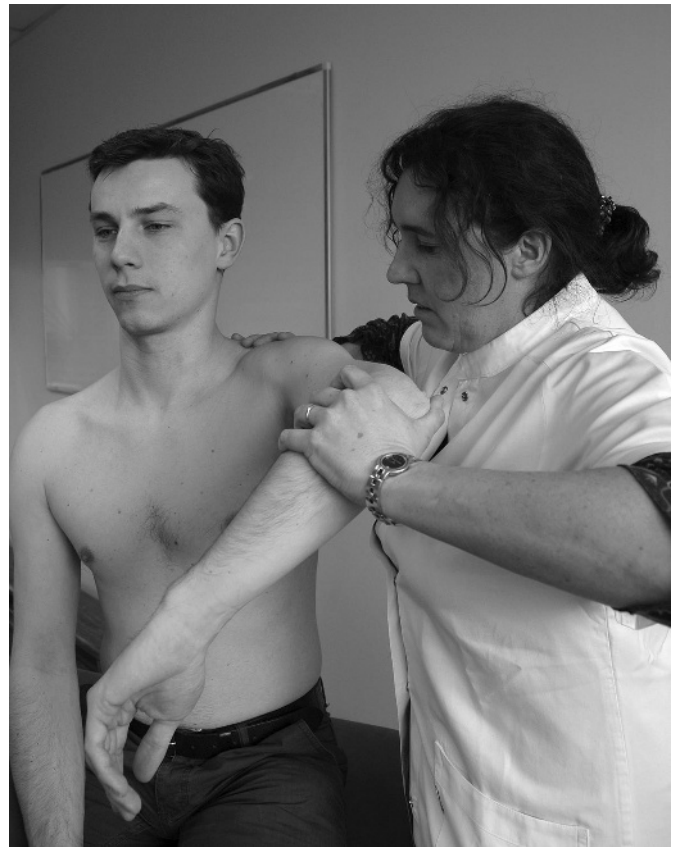


Figure 12 The posterior subluxation test: the patient's arm is placed in adduction, internal rotation and 70 to 90° flexion. The examiner applies a posteriorly directed force along the arm, and then slowly moves the shoulder to horizontal abduction and external rotation.

Impingement tests

Impingement tests are known to have high sensitivity, but rather low specificity.^{18 54 55} Hegedus *et al*¹⁸ concluded from their extensive meta-analysis that sensitivity and specificity for the Neer test were 79% and 53% respectively, and for the Hawkins test 79% and 59% respectively. However, most of the studies,

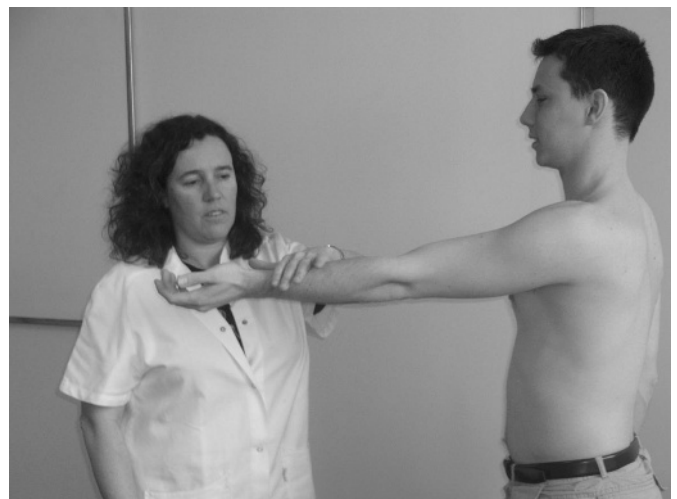
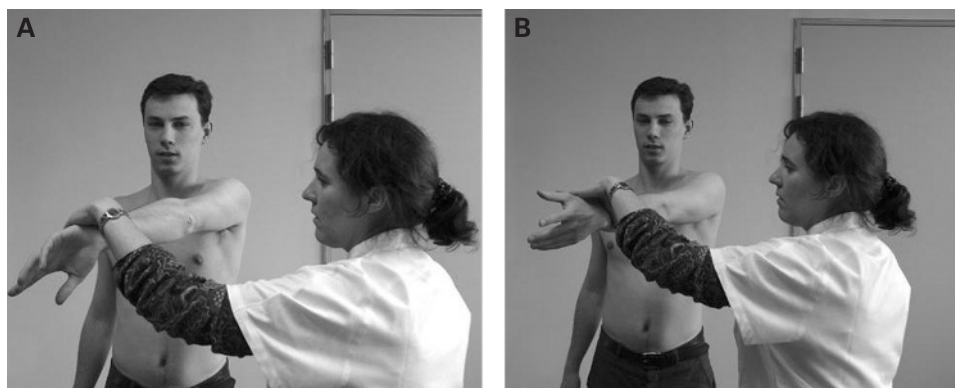


Figure 13 The Speed's test: a downwardly applied pressure is given to the arm when the shoulder is positioned in 90° of forward flexion with the elbow extended, and forearm supinated.

Figure 14 O'Brien test: resistance is tested with the arm forward flexed to 90° and adducted 10° with the thumb pointing down (A), and subsequently with the thumb pointing up (B).



examining accuracy of these tests, use pathologies such as rotator cuff tendinopathy as a reference diagnosis for sensitivity and specificity. On the other hand, several studies confirmed narrowing of the subacromial space during the Neer and Hawkins manoeuvre.²⁷ In addition, Hegedus *et al*¹⁸ recommend using the Hawkins test as a screen, and the supraspinatus/empty-can test may serve as a confirmatory test for impingement. Therefore we believe that these tests should only be used to confirm the presence of impingement symptoms, rather than to identify the underlying pathological mechanism.

The use of instability tests in the evaluation of impingement has been a topic of discussion. Speer *et al*⁴¹ argued that the overall accuracy of the shoulder relocation tests was less than 50% when the response of pain alone was considered, and was higher than 80% when the response of apprehension alone was considered. Based on their results, the authors advised the clinician not to use the criterion of pain in the interpretation of these tests. However, accuracy of this test was investigated in relation to the diagnosis of instability, and not impingement.

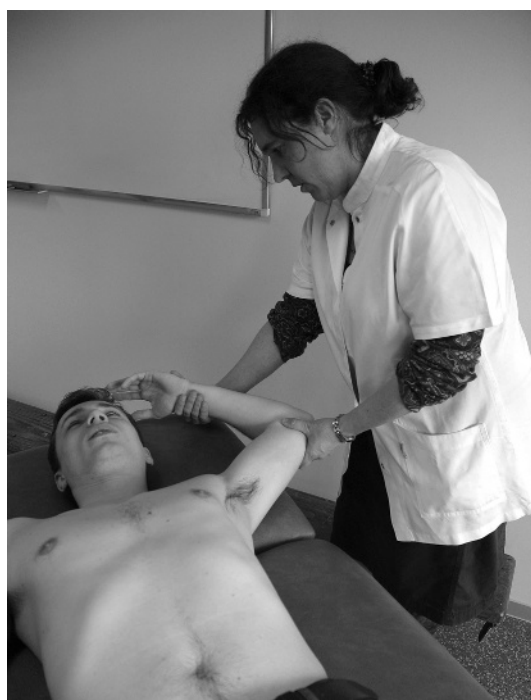

Figure 15 Biceps Load II test: the examiner applies resistance against elbow flexion with the shoulder in 120° of abduction and the elbow in 90° flexion, and the patient in supine position.

Other researchers have used the criteria “pain during apprehension, and disappearance of pain during relocation” in the clinical examination of impingement.^{36–39} Moreover, recently, Meister *et al*⁴⁰ presented a new test for internal impingement, “the posterior impingement sign”, in which the position of the shoulder is the same as during the classical “apprehension” test. Based on the results of the latter study, the clinician may be advised to use the Apprehension position or posterior impingement sign in the detection and location of impingement symptoms, particularly in the overhead athlete with internal impingement signs.

Rotator cuff tests

Various studies have been performed comparing the effectiveness of the “empty-can test” and the “full-can test” in diagnosing supraspinatus pathology or impingement. Several studies showed that both testing positions can be used in diagnosing supraspinatus tears^{43–44–56}; however, in general pain provocation is less in the full-can position.⁵⁶ Therefore it has been suggested to use the full-can position in the diagnosis of rotator cuff tears, and the empty-can test in the detection of subacromial impingement symptoms.

Scapular involvement tests

Only recently, scapular tests have been described in the literature.^{9–45–46–57} These investigation tools try to identify

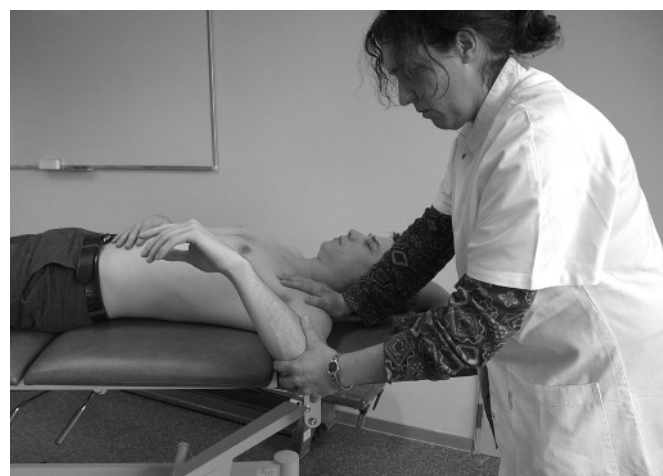

Figure 16 Assessment of GIRD: Glenohumeral internal rotation is measured with the patient in supine position, the shoulder abducted 90°, and the scapula stabilised against the table.

Review

possible scapular involvement in impingement-related shoulder pain. Besides anthropometric measurements of scapular orientation,^{58 59} and clinical qualitative observation of scapular movement patterns,⁵⁷ a few clinical tests have been introduced in literature. Rabin *et al*⁴⁵ examined the intertester reliability of the SAT⁸ on patients with shoulder pain. They concluded that the SAT possesses acceptable inter-rater reliability for clinical use. Kibler *et al*⁴⁶ evaluated apparent and absolute supraspinatus strength in patients with shoulder injury using the SRT. The study showed that apparent supraspinatus muscle weakness on clinical examination in symptomatic patients may be dependent on scapular position, since the patients showed a significant increase in scapular elevation strength during the SRT+Jobe test compared with the normal Jobe test.

Instability tests

Speer *et al*⁴¹ examined the accuracy of the Apprehension and Relocation tests with respect to diagnosing instability. In this study high accuracy was found (85%) if the criterion was "apprehension", or reflexive muscle reaction to protect the glenohumeral joint, but rather low accuracy (49%) if the criterion was only pain. These results were confirmed by Farber *et al*.⁶⁰ However, as mentioned earlier, in this study instability was the only target diagnosis, and not pain based on impingement. Meister *et al*⁴⁰ found high sensitivity (75%) and specificity (85%) for the "posterior impingement sign" in which the shoulder is placed in a position similar to the apprehension position for diagnosing posterosuperior glenoid impingement.

With respect to the laxity tests, a reliability of 0.75 was found for translations of the humeral head in anterior, posterior and inferior positions, when grading the amount of translation from I to III.⁶¹ In general, however, it is recommended to be cautious in interpreting laxity test results, and to combine laxity testing with provocative instability testing in view of clinical reasoning and treatment determination.¹⁷

Biceps pathology and SLAP lesion tests

In general, the Speed's test is considered to be a non-specific but sensitive test for biceps and labral (SLAP) pathology.⁴⁸ In recent literature, there is a tremendous interest in the question of how to diagnose with clinical testing the presence of SLAP lesions.^{18 53} Although a definitive diagnosis of SLAP lesions is typically made by arthroscopic observations, clinical suspicion is important before imaging study. However, symptoms in most patients with SLAP lesions are very often non-specific; patients often complain of clicking, "deep" shoulder pain, functional instability, and dead-arm syndrome.^{13 62} Various studies have been performed examining the diagnostic value of SLAP tests, with conflicting results. In a very recent paper, Oh *et al*⁴⁷ examined the sensitivity, specificity and overall accuracy of 10 SLAP tests, earlier described in literature. The authors concluded that some combinations of two relatively sensitive clinical tests (such as the O'Brien and Apprehension tests) and one relatively specific clinical test (such as the Biceps Load II test) increase the diagnostic efficacy of SLAP lesions. Based on this study, and taking into account the overall limited value of clinical SLAP tests, the abovementioned tests are integrated into the clinical algorithm for impingement-related shoulder pathology.

Clinical evaluation of GIRD

In general, measurement of glenohumeral internal rotation ROM (supine, with the shoulder in 90° abduction) and assessment of horizontal adduction (side-lying) are suggested

What is already known on this topic

Numerous shoulder tests are described for the clinical assessment of impingement-related shoulder pathology. Although the diagnostic value of these individual tests has been examined, the clinician often experiences difficulties selecting the appropriate test and providing the proper interpretation.

What this study adds

This study offers an algorithm for clinical reasoning in which a chronology and interpretation frame may help the therapist in the physical examination of the patient with impingement-related shoulder pain.

to indirectly evaluate stiffness of the posterior shoulder structures.^{32 63–65} According to Riddle *et al*,⁶⁶ goniometric measurements for the shoulder are highly reliable when taken by the same physical therapist. The degree of intertester reliability for these measurements appears to be range-of-motion-specific. Therefore it is advised that the same examiner performs both pretreatment and post-treatment assessments. Recently, Borstad *et al*⁶⁵ evaluated both the internal rotation and the adduction ROM measurement. They concluded that these measures were highly reliable in a healthy population over a short period, but may not be clinically useful in subjects with pathology tested over longer intervals. Therefore, these measurements should be performed with caution, and should be accompanied by thorough physical examination and interpretation of the end-feel during accessory movements such as posterior glenohumeral joint translation.⁵²

The clinical algorithm presented in this paper has some limitations, from a clinical as well as from a scientific point of view. Firstly, not all possible shoulder pain conditions are covered by the model. Diagnoses that will often need further clinical assessment, with additional specific diagnostic clinical tests, as well as ultrasonography, are subacromial bursitis or rotator cuff tears.⁶⁷ This algorithm only offers a clinical reasoning guideline for the initial assessment of the patient. In addition, research in the future should focus on demonstrating that this algorithm has clinical utility.

In summary, we present an algorithm for clinical assessment of impingement-related shoulder pain in the overhead athlete. After identifying the type and the location of the impingement, it is essential to examine the patient further to diagnose underlying causes, such as rotator cuff tendinopathy, scapular dyskinesis, instability, biceps pathology and stiffness of the posterior structures.

Competing interests: None.

Patient consent: Obtained.

REFERENCES

1. Blevins F. Rotator cuff pathology in athletes. *Sports Med* 1997;**24**:205–20.
2. Pink M, Tibone J. The painful shoulder in the swimming athlete. *Orthop Clin North Am* 2000;**31**:247–61.
3. Angelo RL. The overhead athlete: how to examine, test, and treat shoulder injuries. Intra-articular pathology. *Arthroscopy* 2003;**19**:47–50.
4. Neer CS II. Anterior acromioplasty for the chronic impingement syndrome in the shoulder. A preliminary report. *J Bone Joint Surg Am* 1972;**54A**:41–50.
5. Kaplan LD, McMahon PJ, Towers J, *et al*. Internal impingement: findings on magnetic resonance imaging and arthroscopic evaluation. *Arthroscopy* 2004;**20**:701–4.

6. **Jobe C.** Superior glenoid impingement. *Clin Orthop* 1996;**330**:98–107.
7. **Kibler B.** The role of the scapula in athletic shoulder function. *Am J Sports Med* 1998;**26**:325–37.
8. **Burkhart S,** Morgan C, Kibler W. The disabled shoulder: spectrum of pathology part III: the SICK scapula, scapular dyskinesis, the kinetic chain, and rehabilitation. *Arthroscopy* 2003;**19**:641–61.
9. **Cools AM,** Declercq G, Cagnie B, *et al.* Internal impingement in the tennis player: rehabilitation guidelines. *Br J Sports Med* 2007 (epub ahead of print).
10. **Meister K.** Injuries to the shoulder in the throwing athlete. Part one: biomechanics/pathophysiology/classification of injury. *Am J Sports Med* 2000;**28**:265–75.
11. **Morrison DS,** Greenbaum BS, Einhorn A. Shoulder impingement. *Orthop Clin North Am* 2000;**31**:285–93.
12. **Wilk KE,** Meister K, Andrews JR. Current concepts in the rehabilitation of the overhead throwing athlete. *Am J Sports Med* 2002;**30**:136–51.
13. **Burkhart SS,** Morgan CD, Kibler WB. The disabled throwing shoulder: spectrum of pathology: Part I: pathoanatomy and biomechanics. *Arthroscopy* 2003;**19**:404–20.
14. **Borsa PA,** Laudner KG, Saurers EL. Mobility and stability adaptations in the shoulder of the overhead athlete: a theoretical and evidence-based perspective. *Sports Med* 2008;**38**:17–36.
15. **Warner JJ,** Micheli LJ, Arslanian LE, *et al.* Patterns of flexibility, laxity, and strength in normal shoulders and shoulders with instability and impingement. *Am J Sports Med* 1990;**18**:366–75.
16. **Tennent TD,** Beach WR, Meyers JF. A review of the special tests associated with shoulder examination. The rotator cuff tests. *Am J Sports Med* 2003;**31**:154–60.
17. **Tennent TD,** Beach WR, Meyers JF. A review of the special tests associated with shoulder examination. Part II: laxity, instability, and superior labral anterior and posterior (SLAP) lesions. *Am J Sports Med* 2003;**31**:301–7.
18. **Hegedus EJ,** Goode A, Campbell S, *et al.* Physical examination tests of the shoulder: a systematic review with meta-analysis of individual tests. *Br J Sports Med* 2008;**42**:80–92.
19. **Walch G,** Boileau P, Noel E, *et al.* Impingement of the deep surface of the supraspinatus tendon on the posterosuperior glenoid rim: an arthroscopic study. *J Shoulder Elbow Surg* 1992;**1**:238–45.
20. **Gerber G,** Sebesta A. Impingement of the deep surface of the subscapularis tendon and the reflection pulley on the anterosuperior glenoid rim: a preliminary report. *J Shoulder Elbow Surg* 2000;**9**:483–90.
21. **Habermeyer P,** Magosch P, Pritsch M, *et al.* Anterosuperior impingement of the shoulder as a result of pulley lesions: a prospective arthroscopic study. *J Shoulder Elbow Surg* 2004;**13**:5–12.
22. **Halbrecht J,** Tirman P, Atkin D. Internal impingement of the shoulder: comparison of findings between the throwing and non-throwing shoulder of college baseball players. *J Arthroscop Rel Res* 1999;**15**:253–8.
23. **Jobe C,** Coen MJ, Srenar P. Evaluation of Impingement Syndromes in the Overhead-Throwing Athlete. *J Athl Train* 2000;**35**:293–9.
24. **Sørensen A,** Jørgensen U. Secondary impingement in the shoulder. An improved terminology in impingement. *Scand J Med Sci Sports* 2000;**10**:266–78.
25. **Natsis K,** Tsikarakas P, Totlis T, *et al.* Correlation between the four types of acromion and the existence of enthesophytes: a study on 423 dried scapulas and review of the literature. *Clin Anat* 2007;**20**:267–72.
26. **Chang EY,** Moses DA, Babb JS, *et al.* Shoulder impingement: objective 3D shape analysis of acromial morphologic features. *Radiology* 2006;**239**:497–505.
27. **Michener LO,** McClure PW, Karduna AR. Anatomical and biomechanical mechanisms of subacromial impingement syndrome. *Clin Biomech* 2003;**18**:369–79.
28. **Ludewig P,** Cook T. Alterations in shoulder kinematics and associated muscle activity in people with symptoms of shoulder impingement. *Phys Ther* 2000;**80**:276–91.
29. **Rodossy MW,** Harner CD, Fu FH. The role of the long head of the biceps muscle and superior glenoid labrum in anterior stability of the shoulder. *Am J Sports Med* 1994;**22**:121–30.
30. **Pagnani MJ,** Deng XH, Warren RF, *et al.* Role of the long head of the biceps brachii in glenohumeral stability: a biomechanical study in cadavera. *J Shoulder Elbow Surg* 1996;**5**:255–62.
31. **Warner JJ,** McMahon PJ. The role of the long head of the biceps brachii in superior stability of the glenohumeral joint. *J Bone Joint Surg Am* 1995;**77**:366–72.
32. **Myers JB,** Laudner KG, Pasquale MR. Glenohumeral range of motion deficits and posterior shoulder tightness in throwers with pathologic internal impingement. *Am J Sports Med* 2006;**34**:385–91.
33. **Bigliani LU,** Codd TP, Connor PM, *et al.* Shoulder motion and laxity in the professional baseball player. *Am J Sports Med* 1997;**25**:609–13.
34. **Chant CB,** Litchfield R, Griffin S. Humeral head retroversion in competitive baseball players and its relationship to glenohumeral rotation range of motion. *J Orthop Sports Phys Ther* 2007;**37**:514–20.
35. **Johanson MA,** Gonzalez-King BZ. Differential soft tissue diagnosis. In: Donatelli RA, ed. *Physical therapy of the shoulder*. New York: Churchill Livingstone, 2004.
36. **Cools AM,** Witvrouw EE, Declercq GA, *et al.* Scapular muscle recruitment patterns: trapezius muscle latency with and without impingement symptoms. *Am J Sports Med* 2003;**31**:542–9.
37. **Cools A,** Witvrouw E, Declercq G, *et al.* Evaluation of isokinetic force production and associated muscle activity in the scapular rotators during a protraction-retraction movement in overhead athletes with impingement symptoms. *Br J Sports Med* 2004;**38**:64–8.
38. **Cools A,** Witvrouw E, Mahieu N, *et al.* Isokinetic scapular muscle performance in overhead athletes with and without impingement symptoms. *J Athl Train* 2005;**40**:104–10.
39. **Ruwe PA,** Pink M, Jobe FW, *et al.* The normal and the painful shoulders during the breaststroke. Electromyographic and cinematographic analysis of twelve muscles. *Am J Sports Med* 1994;**22**:789–96.
40. **Meister K,** Buckley B, Batts J. The posterior impingement sign: diagnosis of rotator cuff and posterior labral tears secondary to internal impingement in overhead athletes. *Am J Orthop* 2004;**33**:412–15.
41. **Speer KP,** Hannafin JA, Altchek DW, *et al.* An evaluation of the shoulder relocation test. *Am J Sports Med* 1994;**2**:177–83.
42. **Jobe FW,** Moynes DR, Brewster CE. Rehabilitation of shoulder instabilities. *Orthop Clin North Am* 1987;**18**:473–82.
43. **Takeda Y,** Kashiwaguchi S, Endo K, *et al.* The most effective exercise for strengthening the supraspinatus muscle: evaluation by magnetic resonance imaging. *Am J Sports Med* 2002;**30**:374–81.
44. **Reinold JM,** Macrina LC, Wilk KE, *et al.* Electromyographic analysis of the supraspinatus and deltoid muscles during 3 common rehabilitation exercises. *J Athl Train* 2007;**42**:464–69.
45. **Rabin A,** Irrgang JJ, Fitzgerald GK, *et al.* The intertester reliability of the Scapular Assistance Test. *J Orthop Sports Phys Ther* 2006;**36**:653–60.
46. **Kibler WB,** Sciascia A, Dome D. Evaluation of apparent and absolute supraspinatus strength in patients with shoulder injury using the scapular retraction test. *Am J Sports Med* 2006;**34**:1643–7.
47. **Oh JH,** Kim JY, Kim WS, *et al.* The evaluation of various physical examinations for the diagnosis of type II superior labrum anterior and posterior lesion. *Am J Sports Med* 2008;**36**:353–9.
48. **Bennett WF.** Specificity of the Speed's test: arthroscopic technique for evaluating the biceps tendon at the level of the bicipital groove. *Arthroscopy* 1998;**14**:789–96.
49. **O'Brien SJ,** Pagnani MJ, Fealy S, *et al.* The active compression test: a new and effective test for diagnosing labral tears and acromioclavicular joint abnormality. *Am J Sports Med* 1998;**26**:610–13.
50. **Kim SH,** Ha KI, Ahn JH, *et al.* Biceps load test II: A clinical test for SLAP lesions of the shoulder. *Arthroscopy* 2001;**17**:160–4.
51. **Myers JB,** Oyama S, Wassinger CA, *et al.* Reliability, precision, accuracy, and validity of posterior shoulder tightness assessment in overhead athletes. *Am J Sports Med* 2007;**35**:1922–30.
52. **Ellenbecker T.** *Shoulder Rehabilitation: Non-operative Treatment*. New York: Thieme, 2006:180.
53. **Guanche CA,** Jones DC. Clinical tests for tears of the glenoid labrum. *Arthroscopy* 2003;**19**:517–23.
54. **Leroux JL,** Thomas E, Bonnel F, *et al.* Diagnostic value of clinical tests for shoulder impingement syndrome. *Rev Rhum Engl Ed* 1995;**62**:423–8.
55. **Calis M,** Akgün K, Birtane M, *et al.* Diagnostic values of clinical diagnostic tests in subacromial impingement syndrome. *Ann Rheum Dis* 2000;**59**:44–7.
56. **Itoi E,** Kido T, Sano A, *et al.* Which is more useful, the "full can test" or the "empty can test," in detecting the torn supraspinatus tendon? *Am J Sports Med* 1999;**27**:65–8.
57. **Kibler WB,** Uhl TL, Maddux JW, *et al.* Qualitative clinical evaluation of scapular dysfunction: a reliability study. *J Shoulder Elbow Surg* 2002;**11**:550–6.
58. **DiVeta J,** Walker ML, Skibinski B. Relationship between performance of selected scapular muscles and scapular abduction in standing subjects. *Phys Ther* 1990;**70**:470–6.
59. **Odom CJ,** Taylor AB, Hurd CE, *et al.* Measurement of scapular asymmetry and assessment of shoulder dysfunction using the Lateral Scapular Slide Test: a reliability and validity study. *Phys Ther* 2001;**81**:799–809.
60. **Farber AJ,** Castillo R, Clough M, *et al.* Clinical assessment of three common tests for traumatic anterior shoulder instability. *J Bone Joint Surg Am* 2006;**88**:1467–74.
61. **Park HB,** Yokota A, Gill HS, *et al.* Diagnostic accuracy of clinical tests for the different degrees of subacromial impingement syndrome. *J Bone Joint Surg Am* 2005;**87**:1446–55.
62. **Nam EK,** Snyder SJ. The diagnosis and treatment of superior labrum, anterior and posterior (SLAP) lesions. *Am J Sports Med* 2003;**31**:798–810.
63. **Tyler TF,** Nicholas SJ, Roy T, *et al.* Quantification of posterior capsule tightness and motion loss in patients with shoulder impingement. *Am J Sports Med* 2000;**28**:668–73.
64. **Laudner KG,** Stanek JM, Meister K. Assessing posterior shoulder contracture: the reliability and validity of measuring glenohumeral joint horizontal adduction. *J Athl Train* 2006;**41**:375–80.
65. **Borstad JD,** Mathiowetz KM, Minday LE, *et al.* Clinical measurement of posterior shoulder flexibility. *Man Ther* 2007;**12**:386–9.
66. **Riddle DL,** Rothstein JM, Lamb RL. Goniometric reliability in a clinical setting. Shoulder measurements. *Phys Ther* 1987;**67**:668–73.
67. **Awerbuch MS.** The clinical utility of ultrasonography for rotator cuff disease, shoulder impingement syndrome and subacromial bursitis. *Med J Aust* 2008;**188**:50–3.